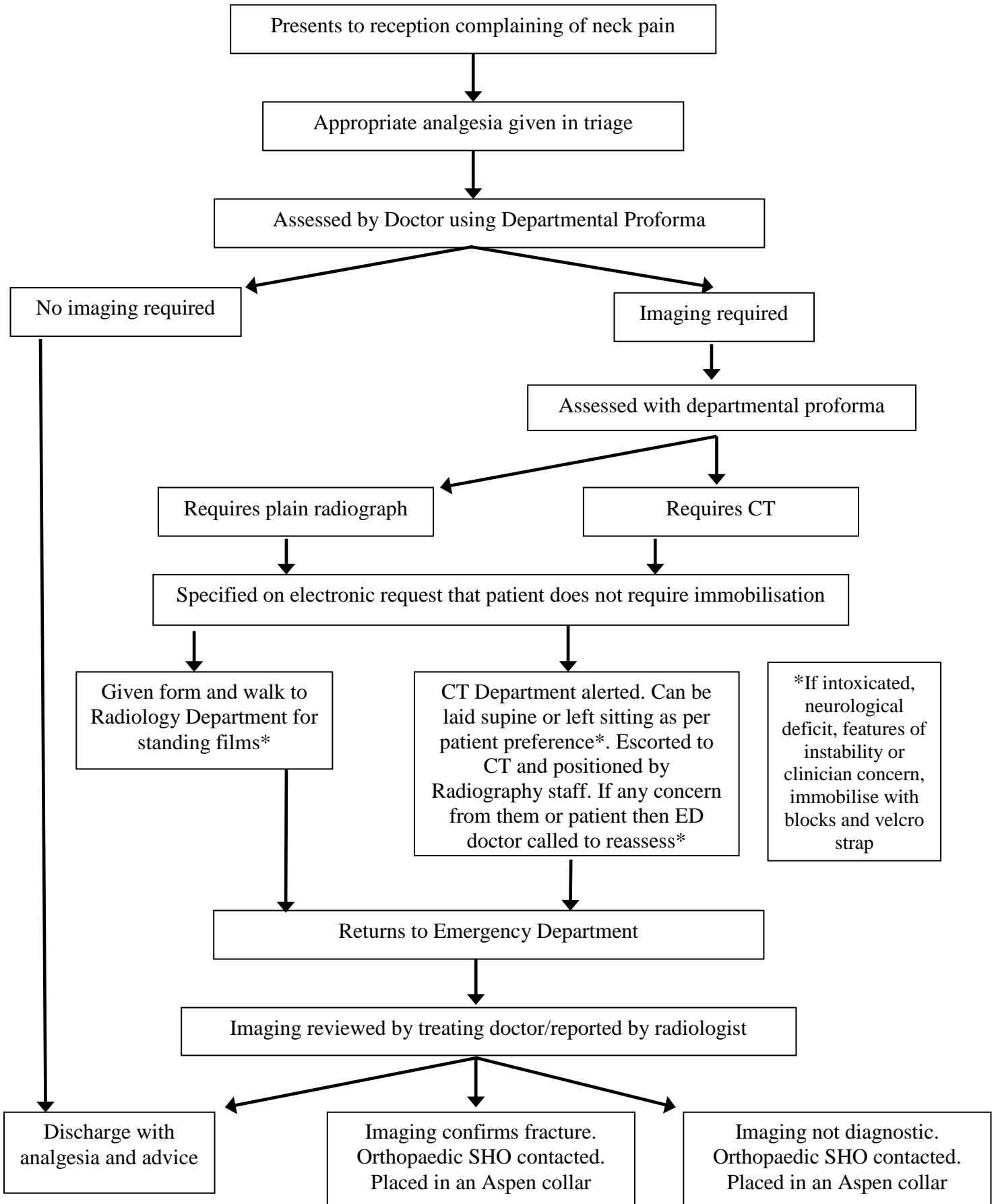


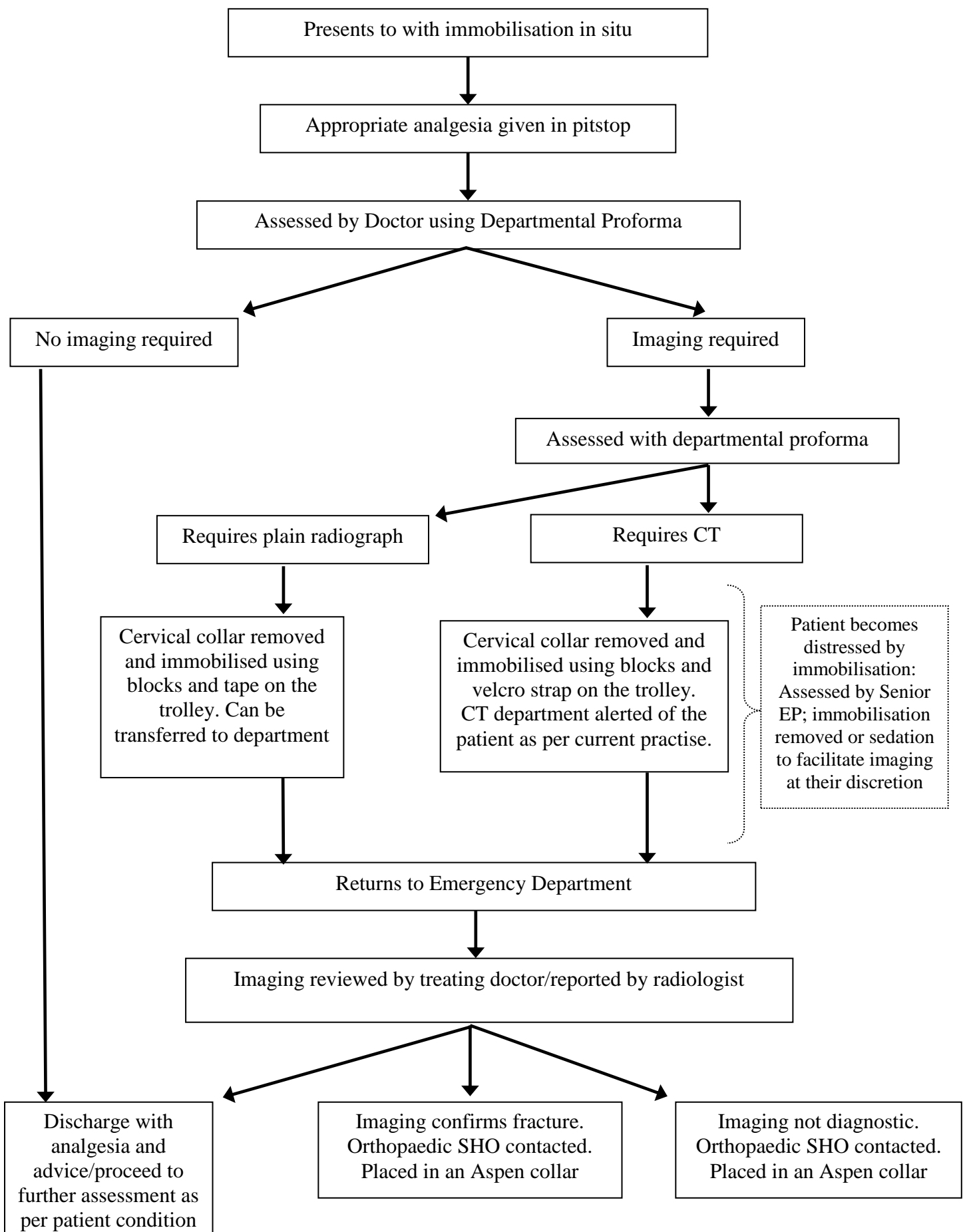
Cervical Spine - Summary Clinical Guideline

Reference No.:CG-EMD/2018/010

Example Patient Flow – Self Presenting



Example Patient Flow – Presents via Ambulance



Cervical Spine Assessment Proforma

Patient Identification Label here

Inclusion Criteria: Blunt trauma with a mechanism that may have injured the neck

Exclusion Criteria: Age <16, Major Trauma (patient in resus).

If **ANY** of the criteria in section 1 are met **DO NOT** assess range of movement (ROM).
Request imaging as per section 3.

1. ANY of:

GCS <15 in ED	
Neurological symptoms	
Deranged observations	
Severe neck pain ($\geq 7/10$)	

No neck pain but dangerous mechanism* AND any of:

Visible injury above the clavicles	
Thoracic injury with severe pain	

*see reverse

Neck pain and ANY of:

Fall from >1m/5 stairs	
Axial load injury (e.g. diving)	
High speed RTC (>60mph closing speed)	
RTC with rollover or ejection	
Motorised recreational vehicle accident**	
Bicycle/Motorbike collision	
Age ≥ 65	
Injury ≥ 48 hours ago	
Re-attending with same injury	
Known vertebral disease	
Risk factor for fragility fracture***	

If **ANY** of the criteria in section 1 are met **DO NOT** assess range of movement (ROM).

2. If **NO** ticks above then are there **ANY** of the low risk features below? If yes then assess ROM.

Any tick = assess range of movement:

Simple rear-end RTC****	
Sitting position in the ED	
Ambulatory at any time since the injury	
Delayed onset of neck pain	
Absence of midline spinal tenderness	

*see reverse

Lateral ROM > 45 degrees	Yes	No	N/A

If YES: Cervical spine cleared clinically

If NO/NA: Request imaging as per section 3

3. **Modality decision-making** –ANY tick below then request CT Cervical Spine. If no criteria below are met and imaging is required then request plain films.

Suspicion or certainty of abnormality on plain films	
Requires CT of another body region due to trauma	
Neurological signs/symptoms referable to C-spine	
Age ≥ 65	
Head injury AND dangerous mechanism*	

Dementia or GCS <13	
Intubated patient	
Inadequate plain film series	
Severe neck pain ($\geq 7/10$)	
Known vertebral disease	

Imaging required (circle): XR / CT / None

Name (Print):

Date:

Signature:

Time: